Printemps 2015 de la médecine d'urgence

Les subtilités de l'ECG dans le SCA avec sus-ST (cas cliniques)

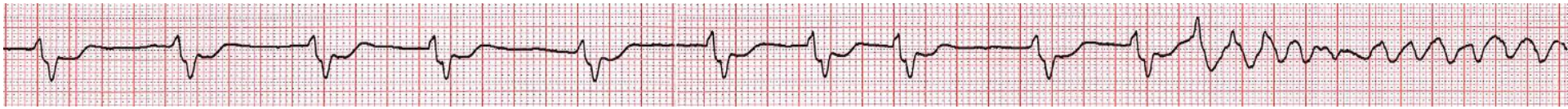

Lyon – 12 mai 2015

Olivier Peyrony

Service des Urgences – Hôpital Saint-Louis

Hôpitaux Universitaires
SAINT-LOUIS
LARIBOISIÈRE
FERNAND-WIDAL

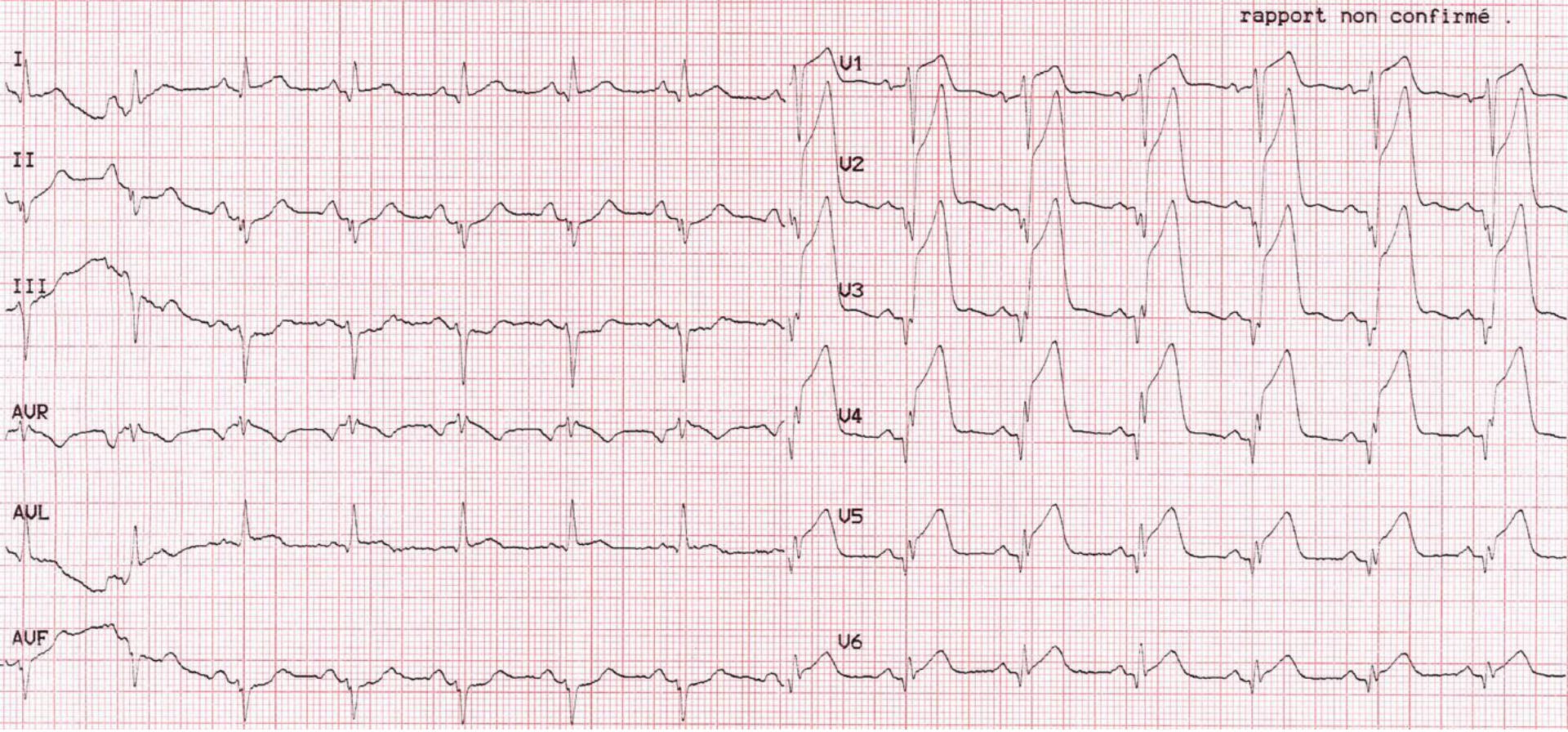

1 – Péricardite

2 – Repolarisation précoce

3 – Brugada

4 – IDM

5 – Hyperkaliémie



53

Femme, 43 ans, DT depuis la veille – tropo HS négative

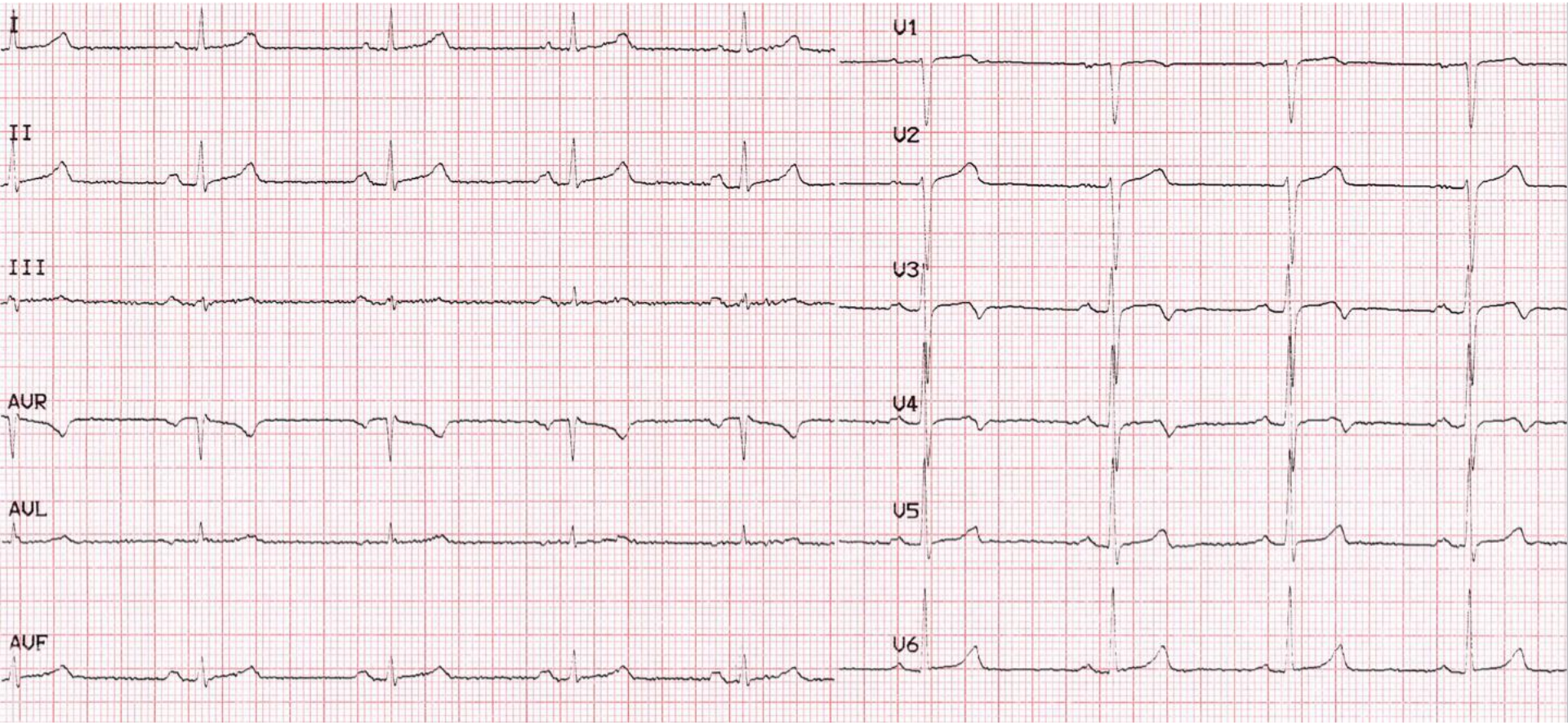

Laissez-vous rentrer cette patiente chez elle?

1 – OUI

2 – NON

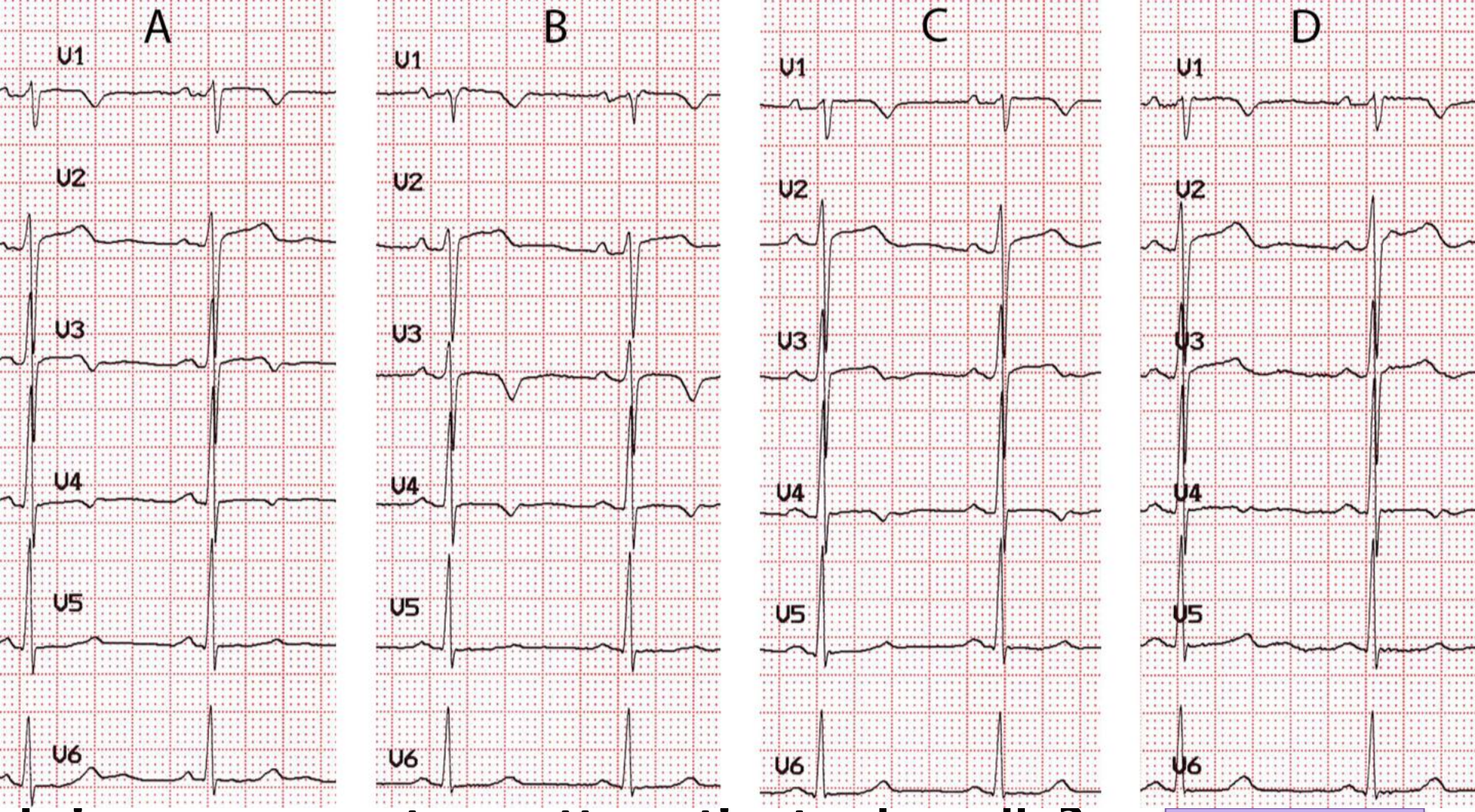

Laissez-vous rentrer cette patiente chez elle?

Sd de Wellens

Characteristic electrocardiographic pattern indicating a critical stenosis high in left anterior descending coronary artery in patients admitted because of impending myocardial infarction

Chris de Zwaan, M.D., Frits W. H. M. Bär, M.D., and Hein J. J. Wellens, M.D.
Maastricht, The Netherlands

1 – OUI

2 – NON

Am Heart J, 1982

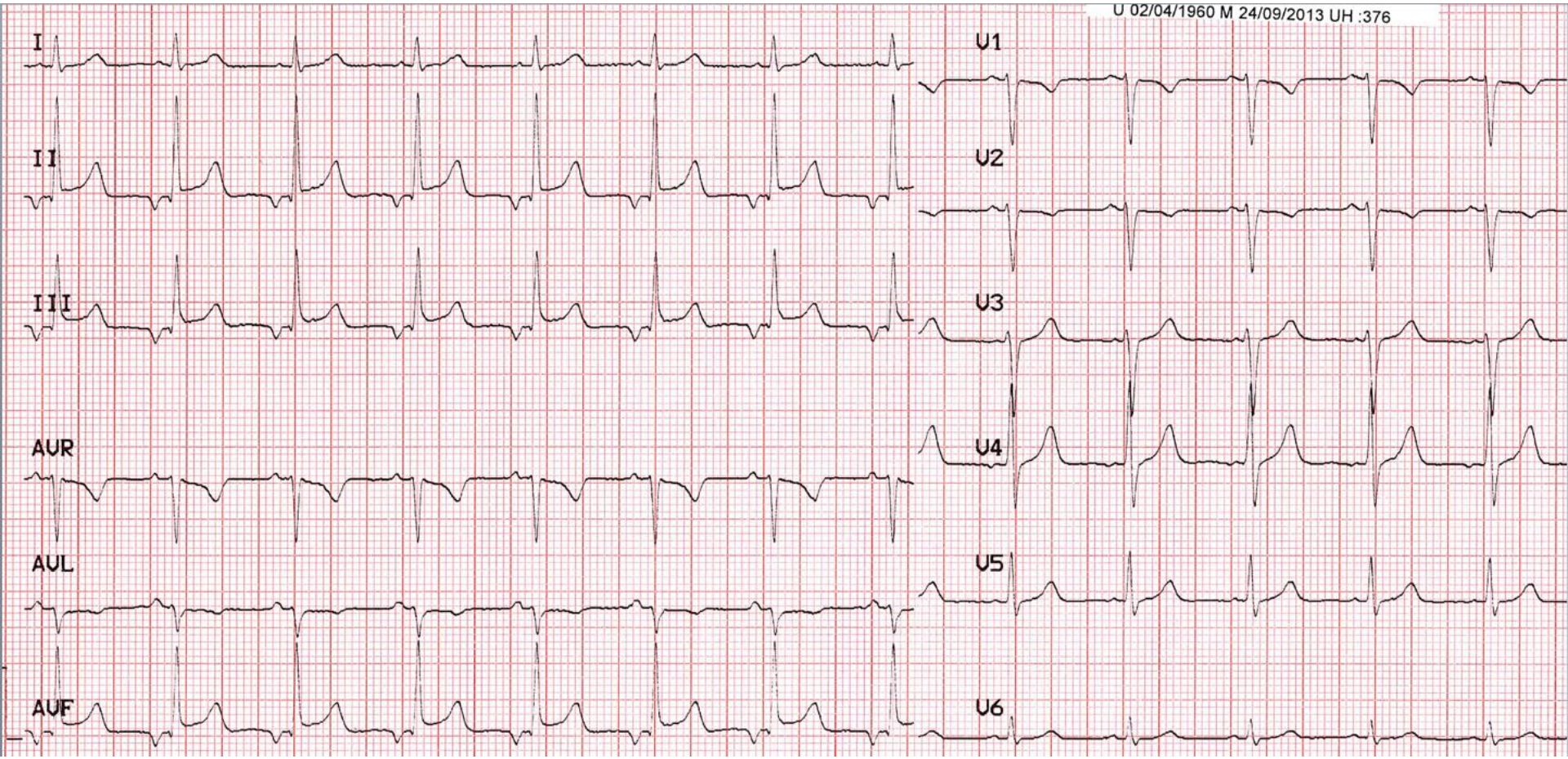

SCA ST+?

1 – OUI

2 – NON

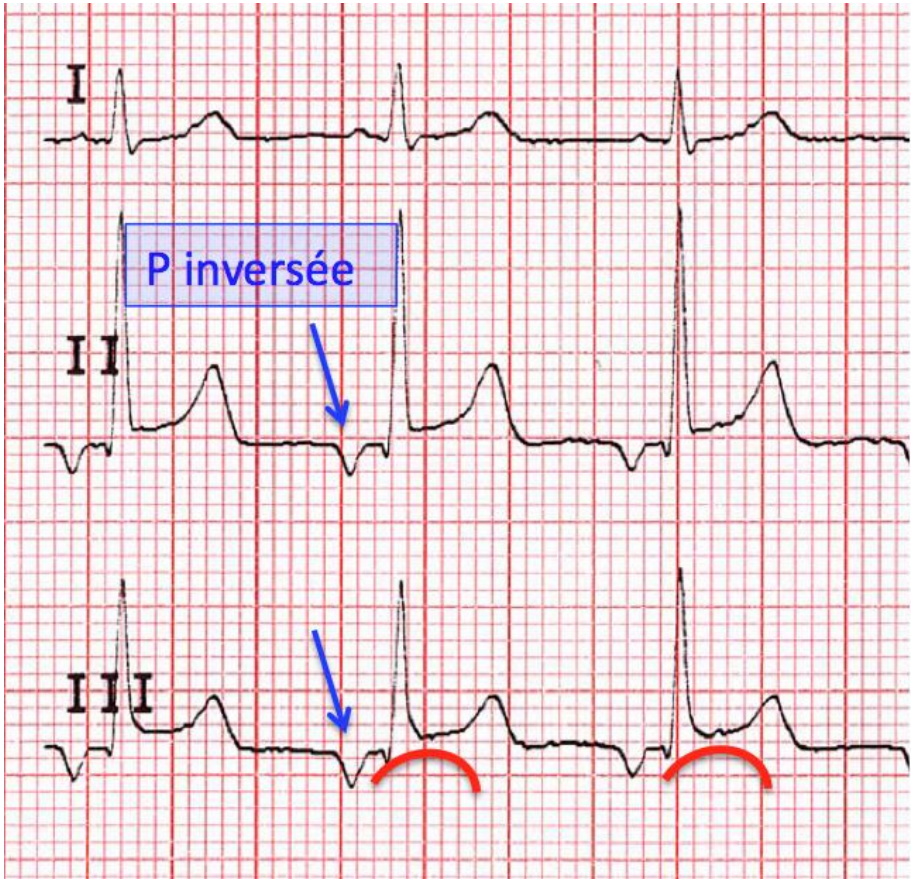

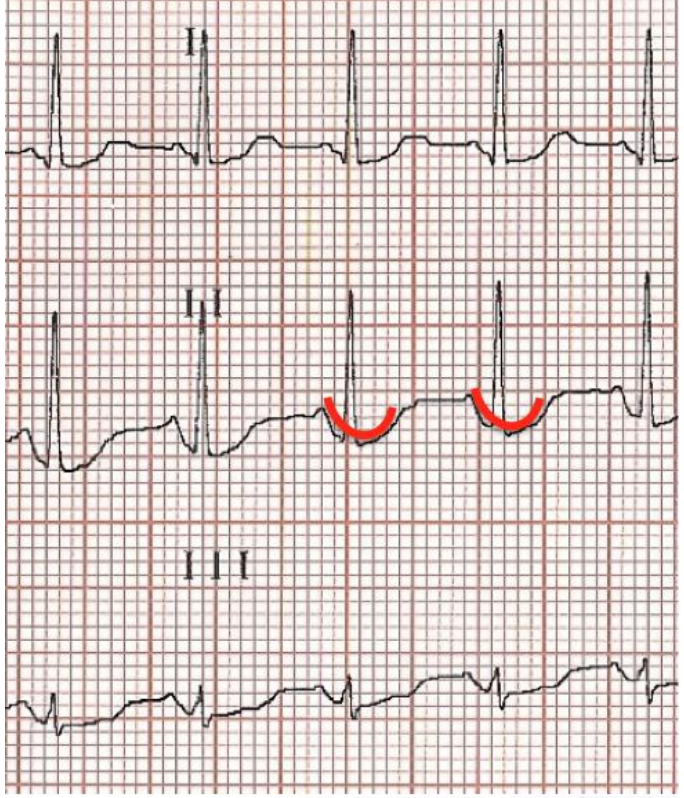

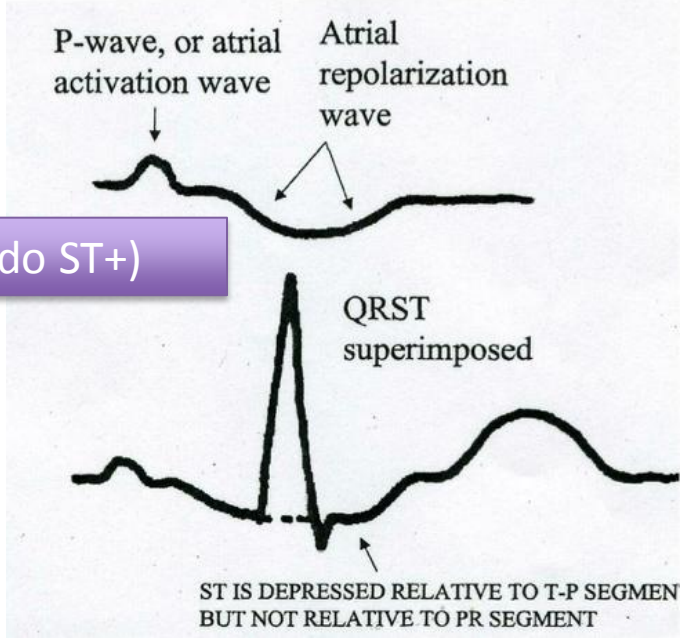

Rythme du sinus coronaire et repolarisation atriale (pseudo ST+)

SCA ST+?

1 – OUI

2 – NON

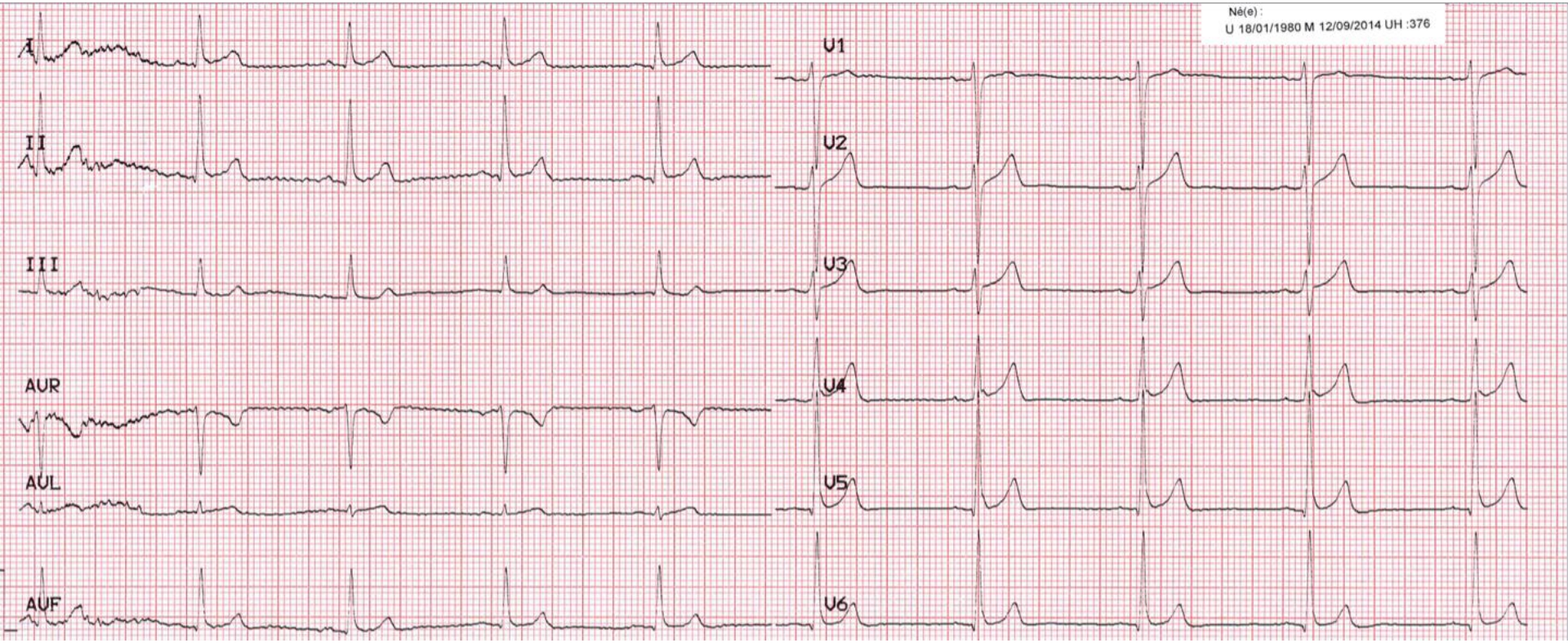

SCA ST+?

1 – OUI

2 – NON

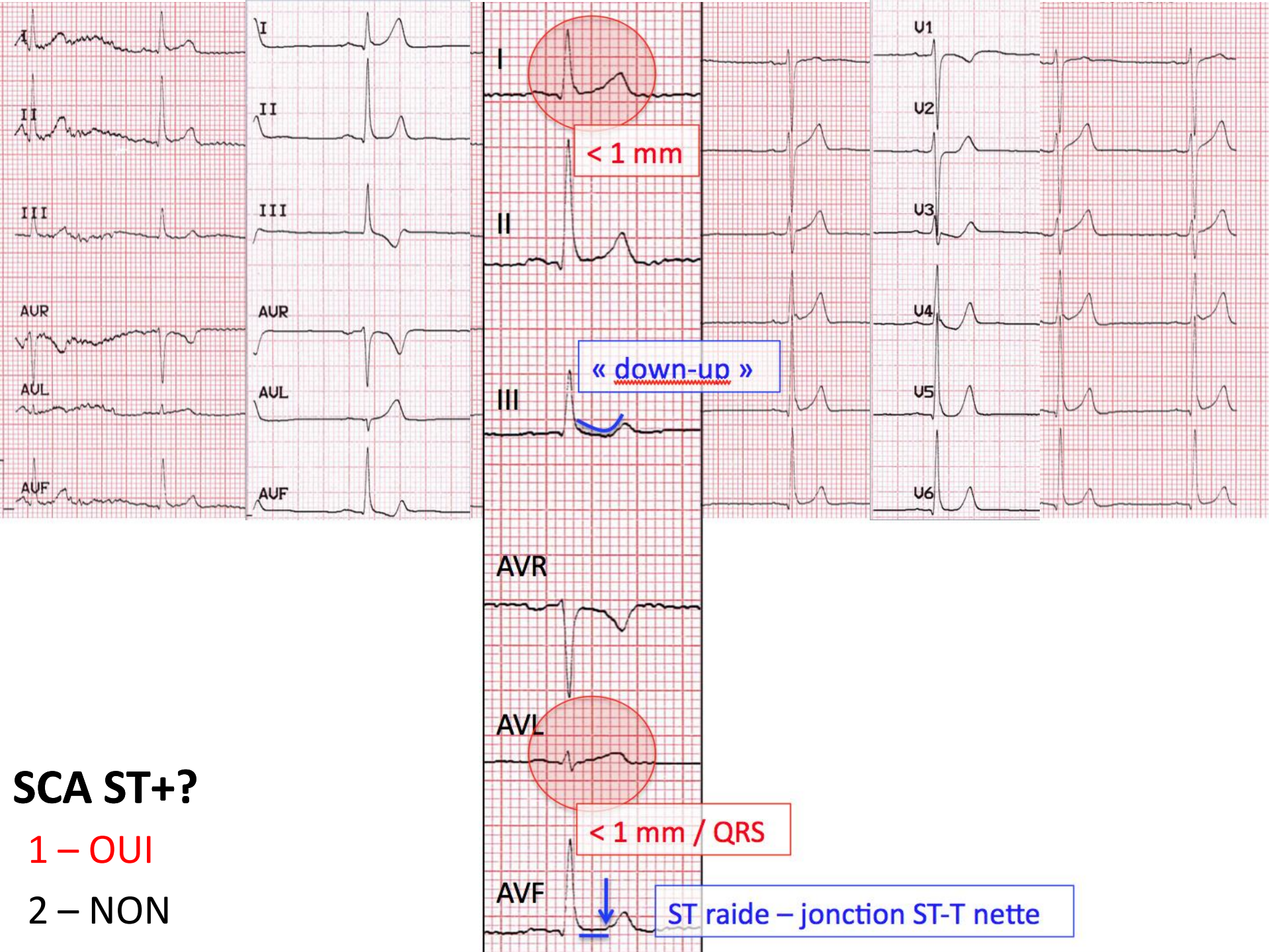

SCA ST+?

1 – OUI

2 – NON

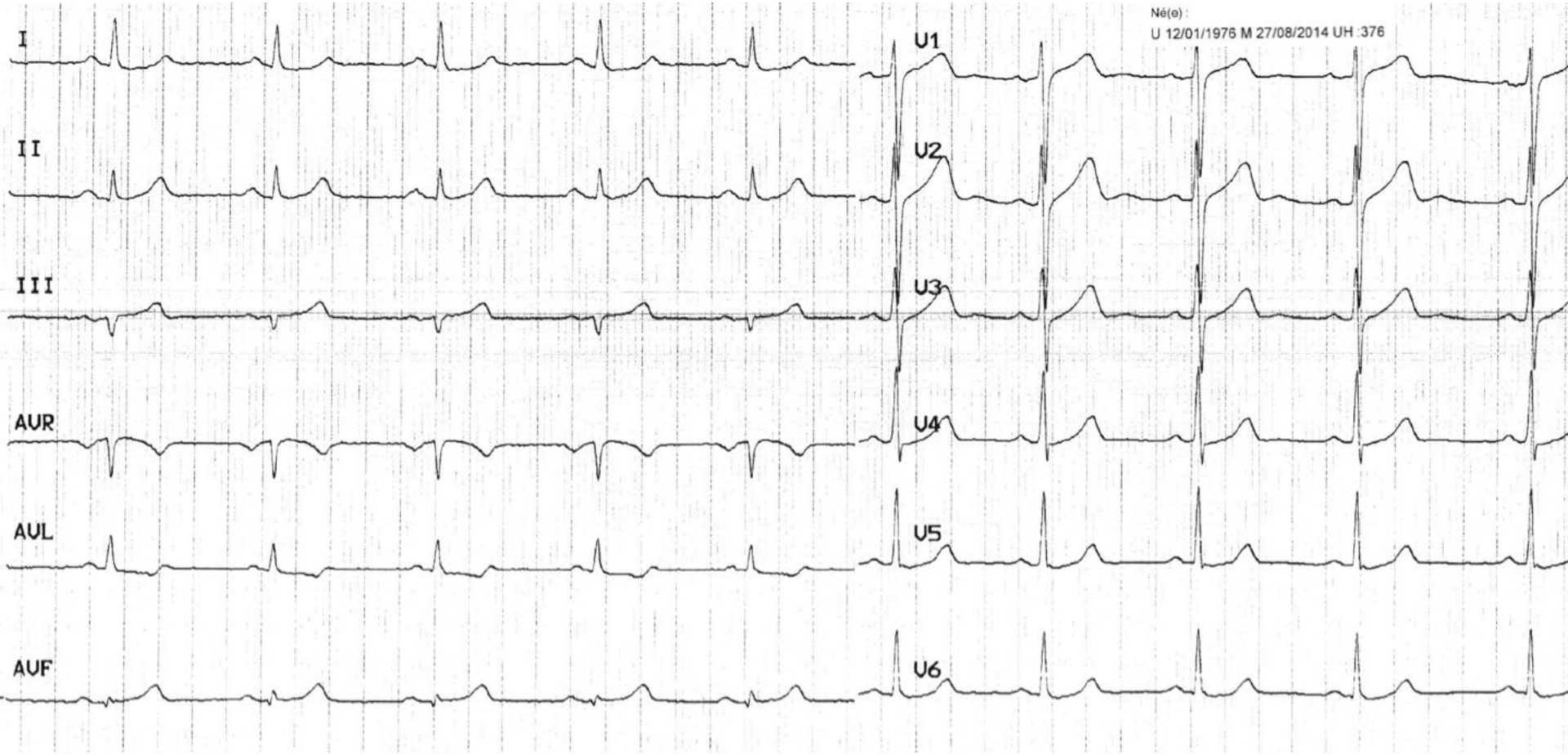

SCA ST+?

1 – OUI

2 – NON

27/08/2014 12:15

ECG :
RRS a 63bpm, axe normal, QRS fins, sus ST en inferieur: D2-D3-AVF avec une onde T negative en AVL, pas de trouble du rythme ni de la conduction
Radio thorax :coeur discretement globuleux, pas de CMG pas d'epanchement
-abdomen souple depressible indolore
au total: patient de 38ans, sans FRCV consulte pour malaise avec douleur thoracique atypique avec des modifications electriques: bio+tropo

le 27/08/2014 17:38

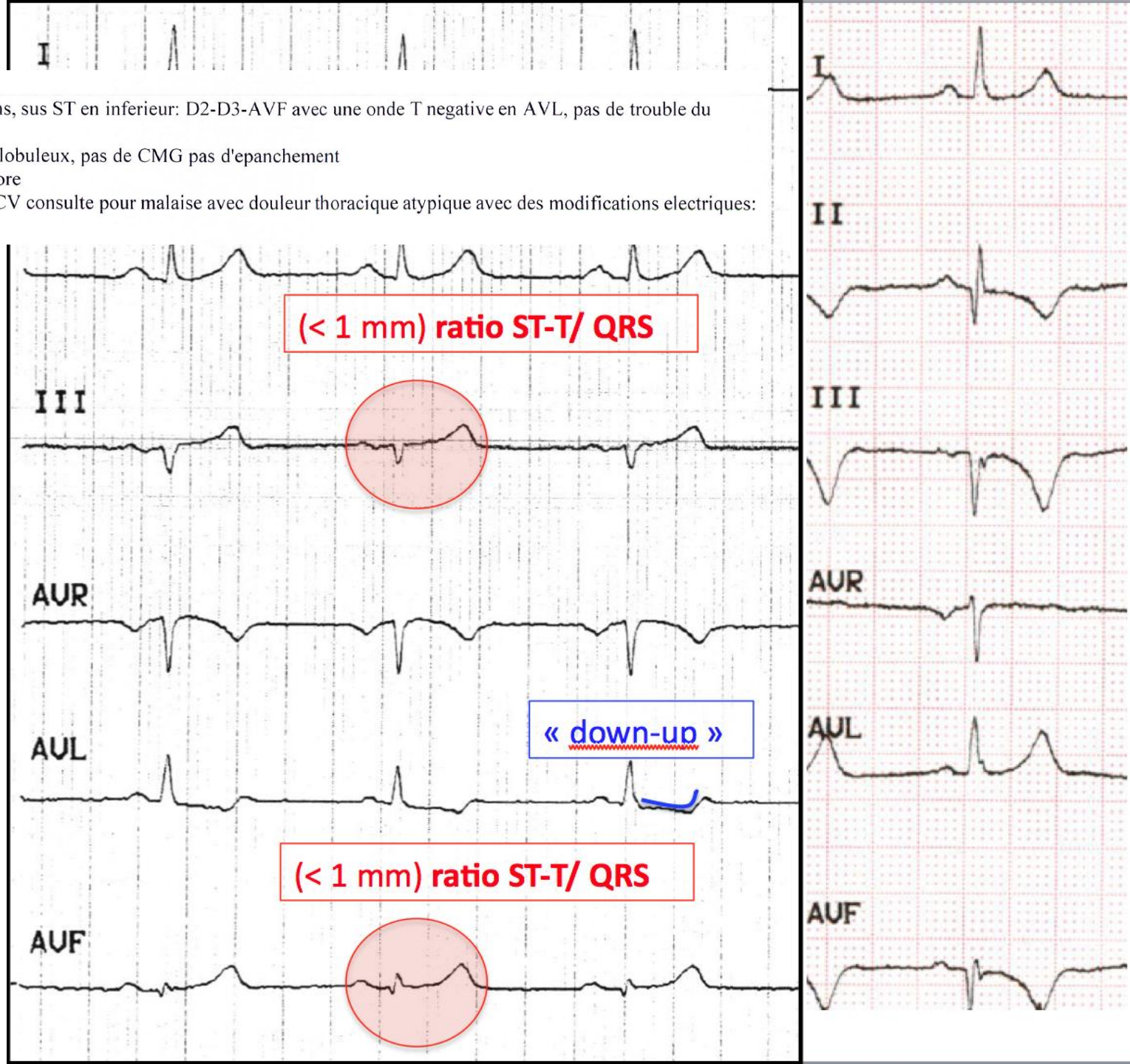

SCA ST+?

1 – OUI

2 – NON

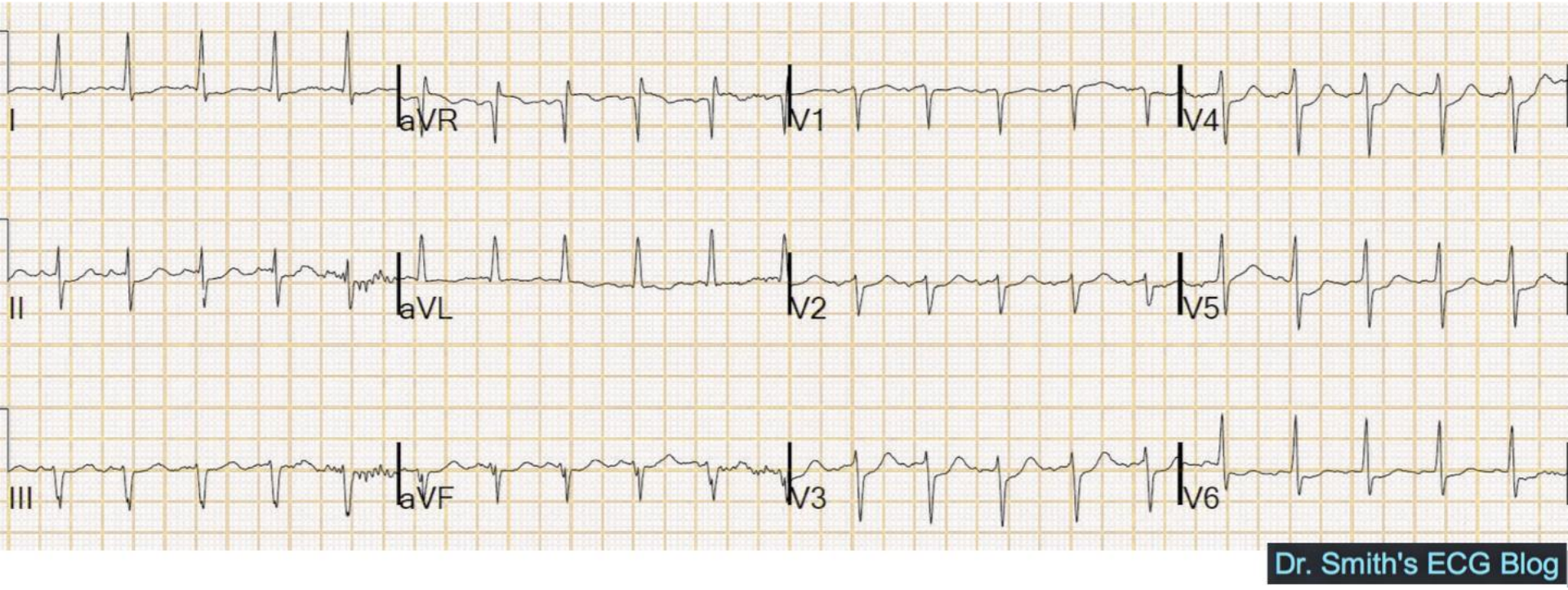

SCA ST+?

1 – OUI

2 – NON

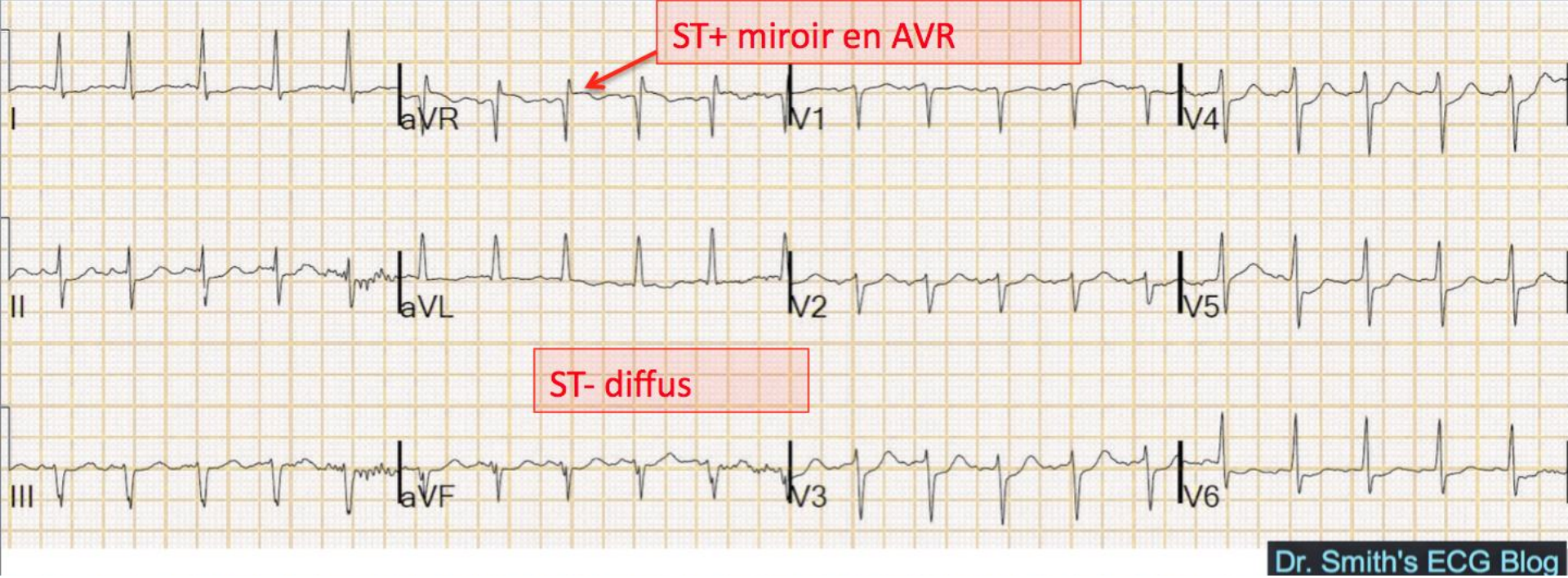

SCA ST+?

Lésions tritronculaires ou tronc commun

1 – OUI (équivalent ST+)

2 – NON

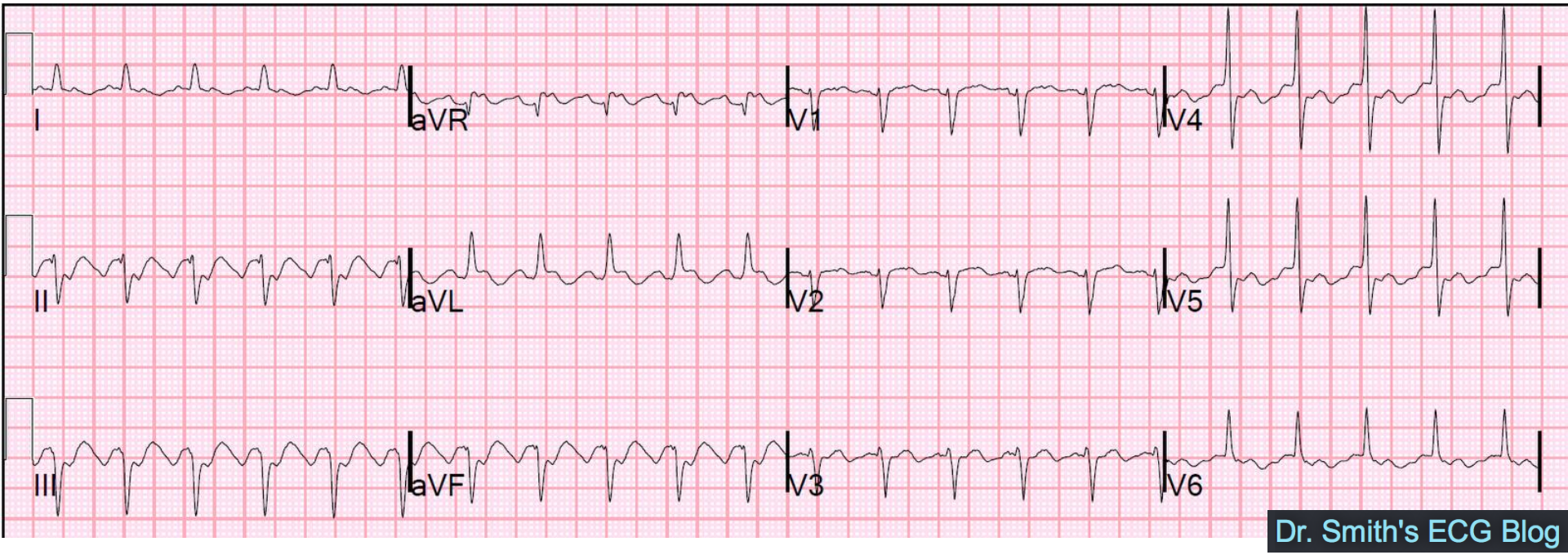

SCA ST+?

1 – OUI

2 – NON

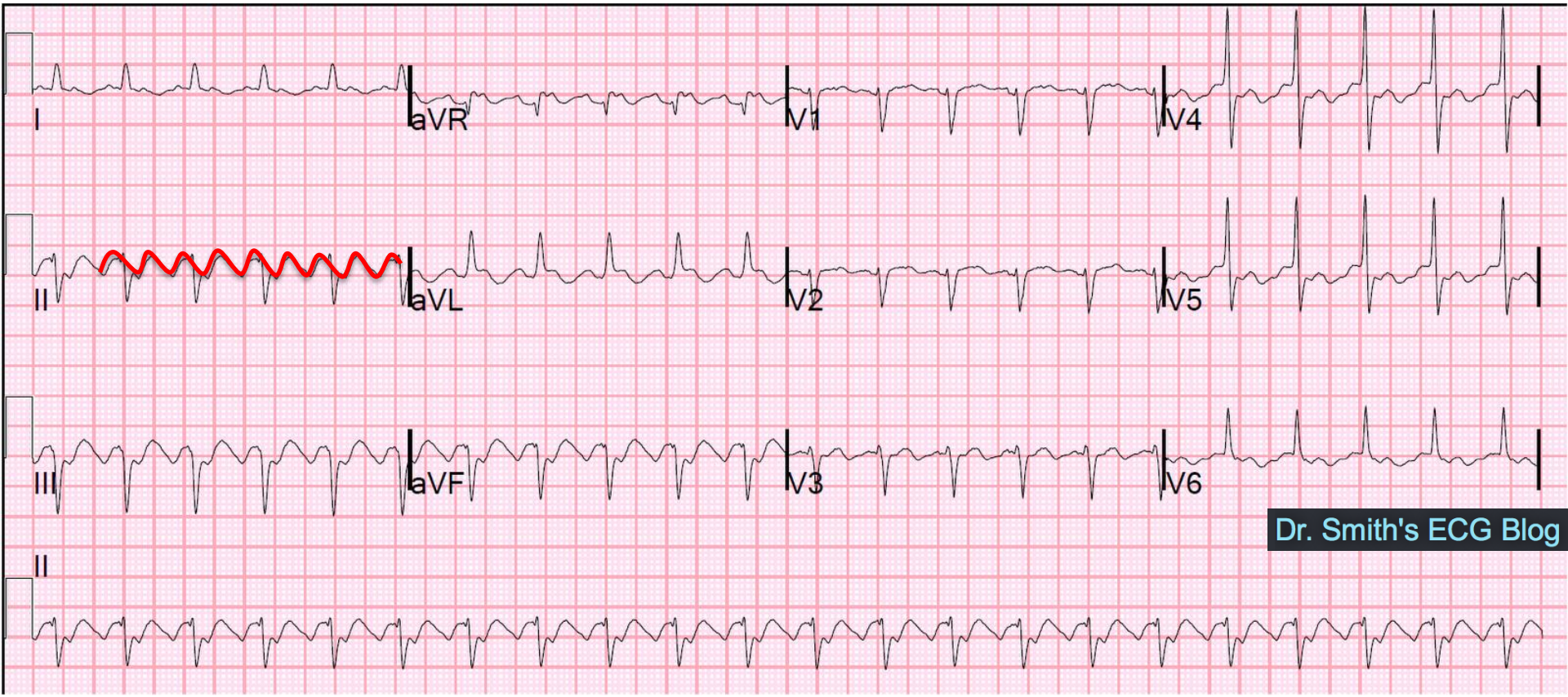

SCA ST+?

Flutter 2:1 (pseudo ST+)

1 – OUI

2 – NON

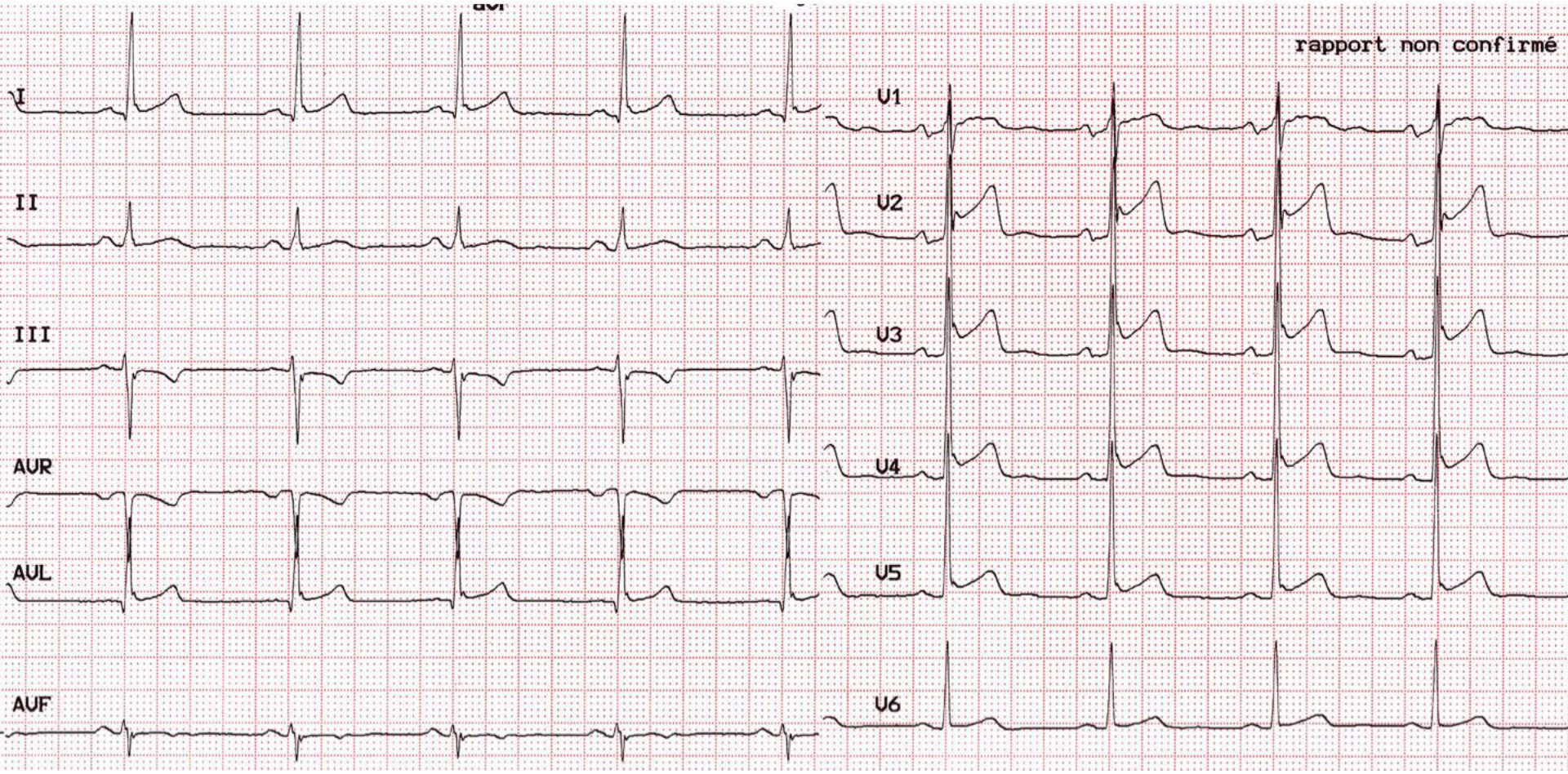

SCA ST+?

1 – OUI

2 – NON

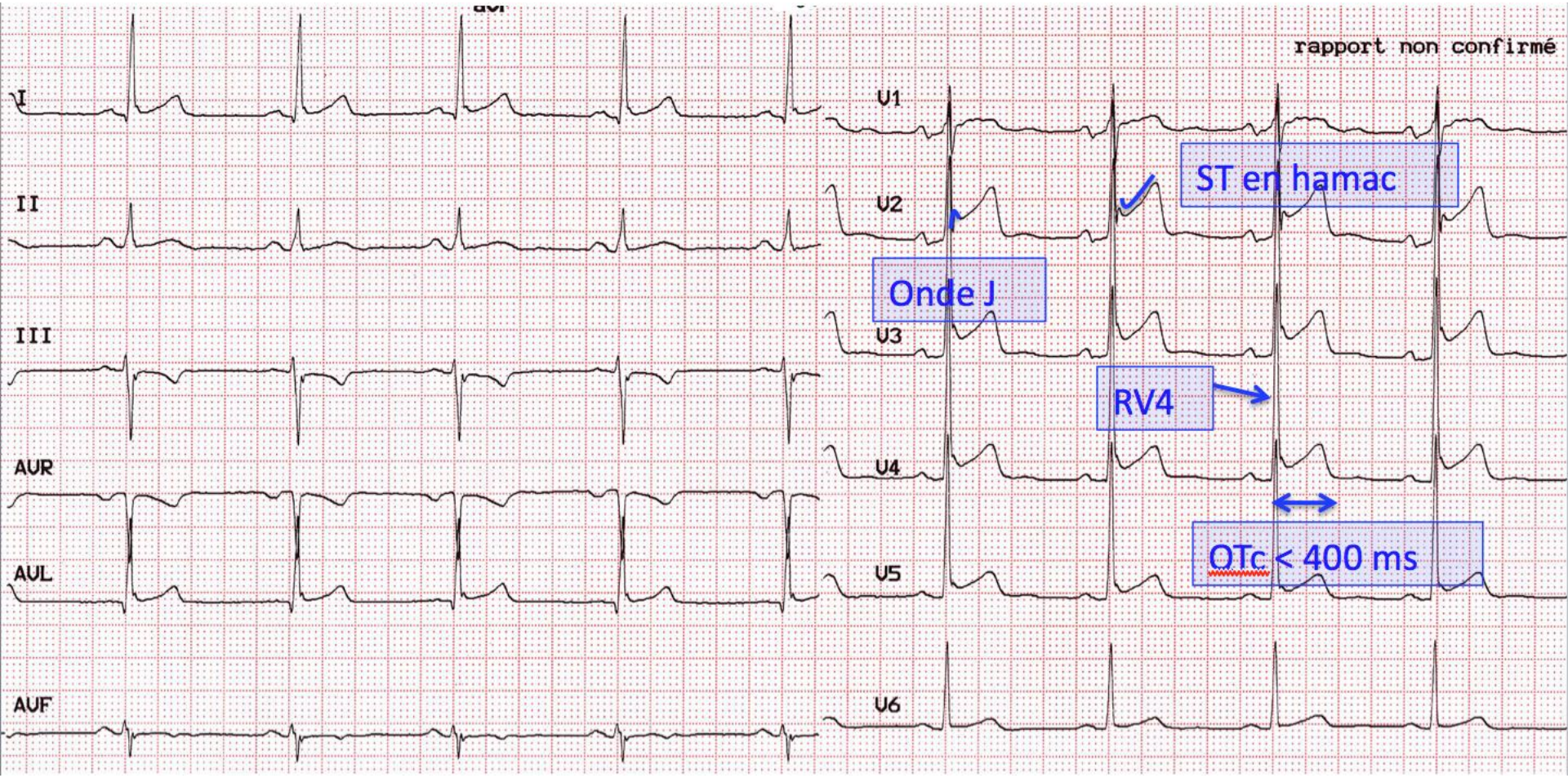

SCA ST+?

1 – OUI

2 – NON

Repolarisation précoce

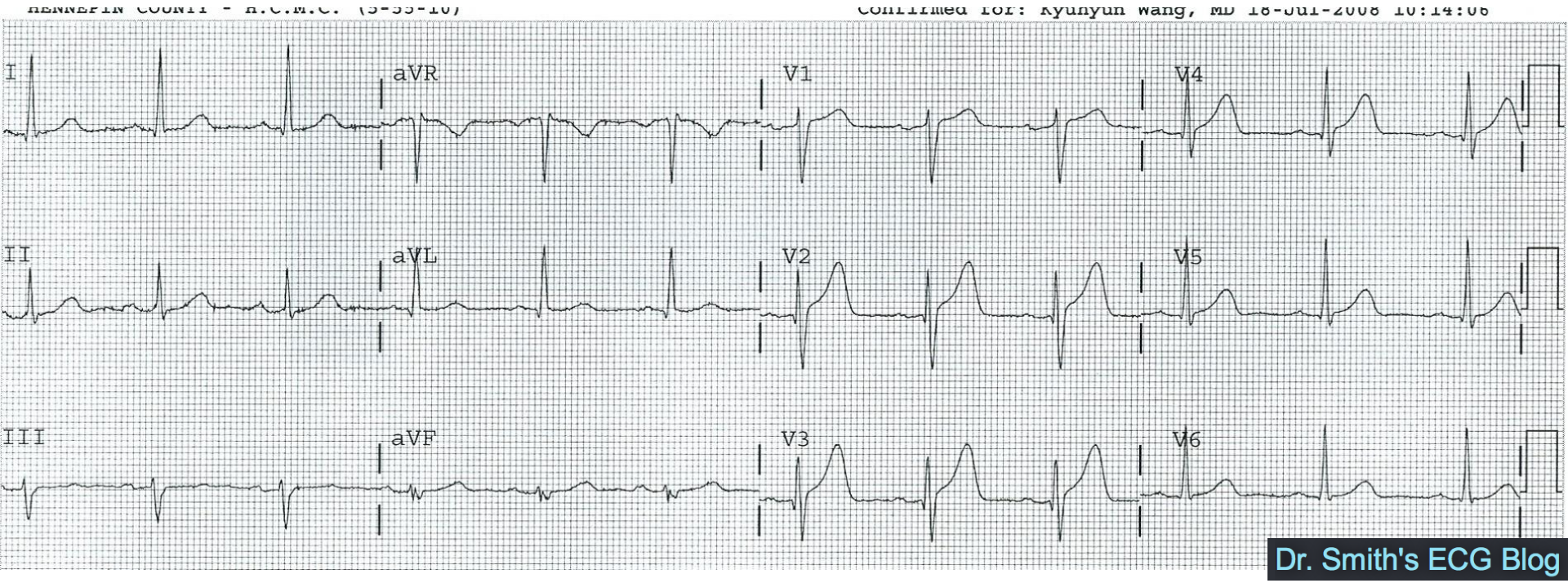

SCA ST+?

1 – OUI

2 – NON

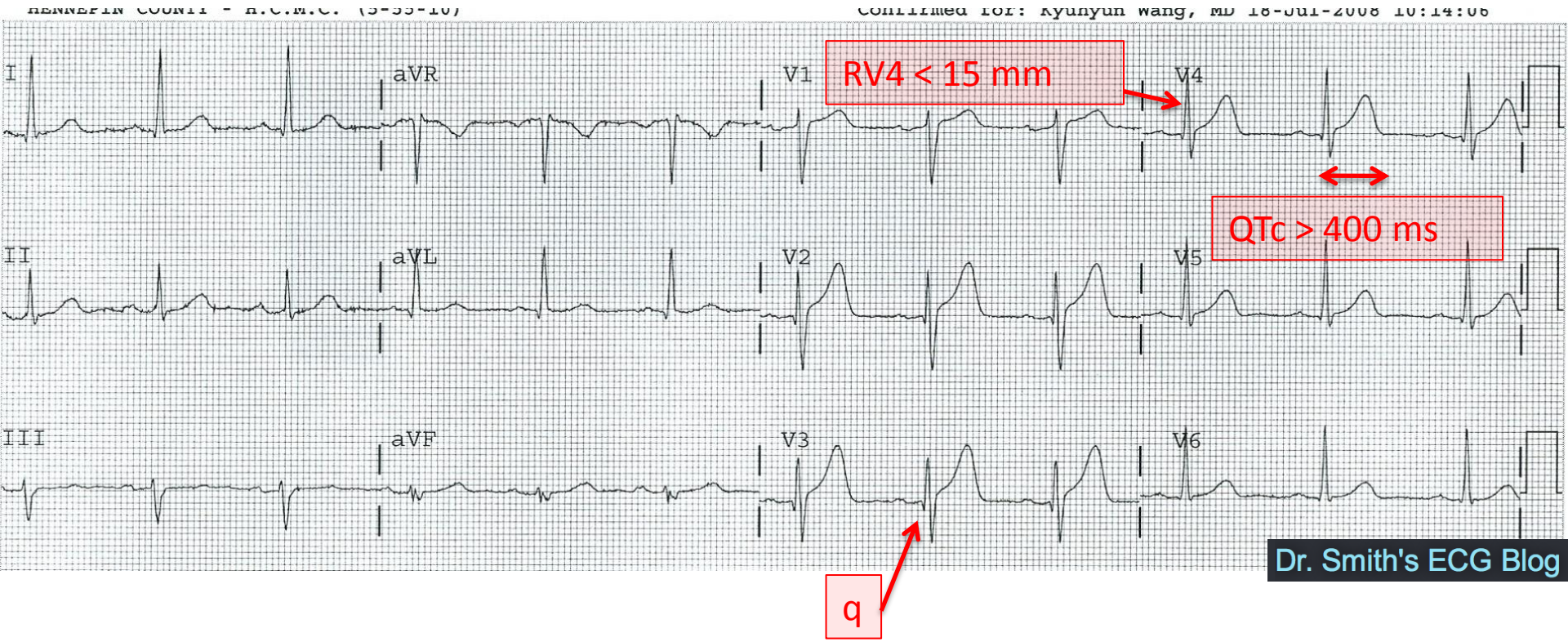

SCA ST+?

1 – OUI

2 – NON

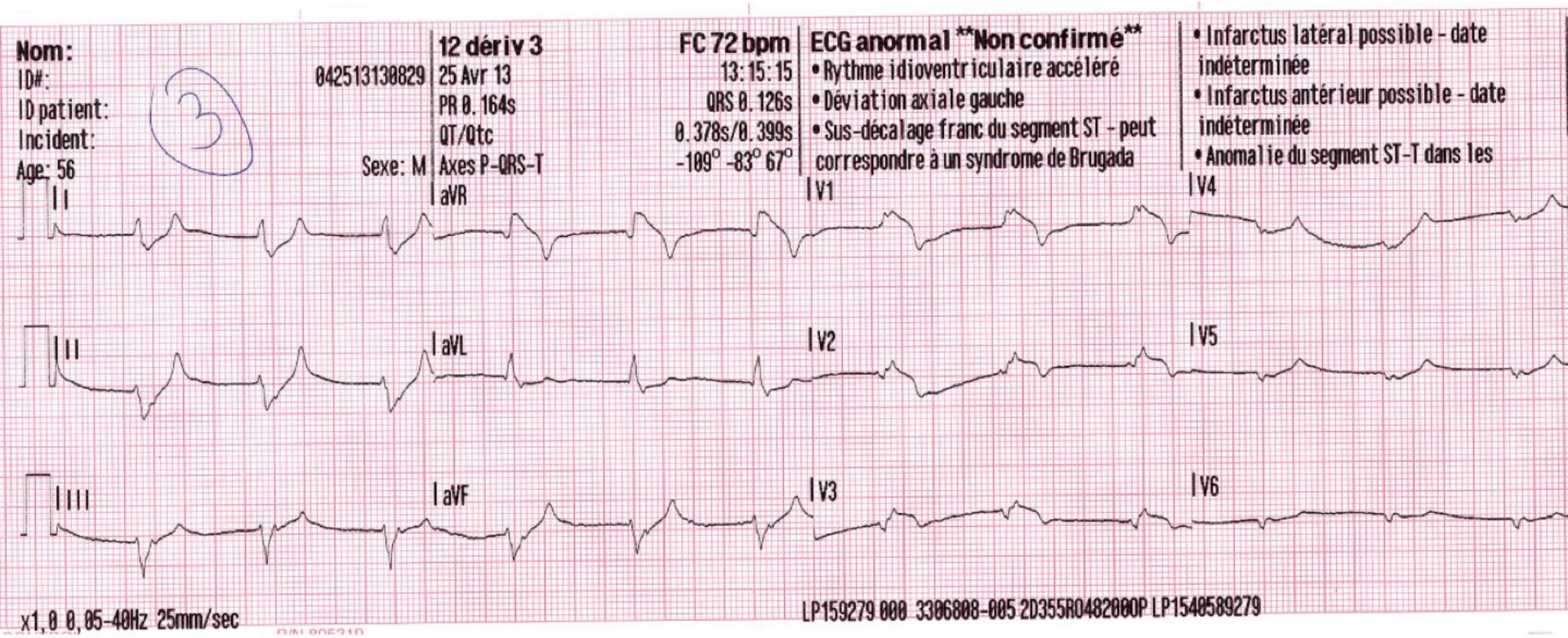

SCA ST+?

1 – OUI

2 – NON

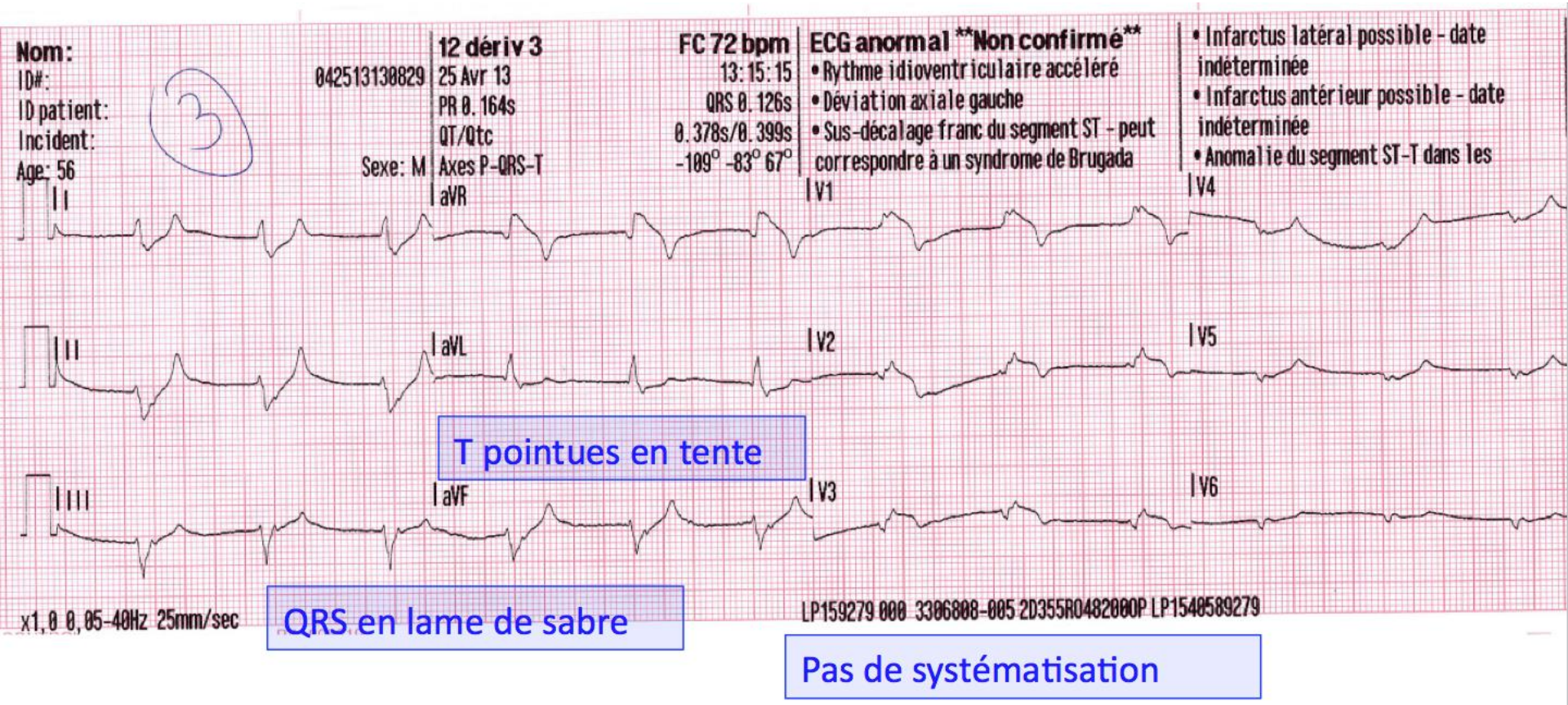

T pointues en tente

QRS en lame de sabre

Pas de systématisation

SCA ST+?

$K^+ = 8$!!

1 – OUI

2 – NON

Le ST+ > 2 mm pose assez peu de problèmes

- Connaître les ST+ non ischémiques

Parfois plus subtil (oubliez le mm!), savoir s'aider :

- QRS - Onde T - Ratio QRS/ST/T
- Miroirs
- **Répéter les ECG +++**
- Tropo (attention angor instable – Wellens)

Dr. Smith's ECG Blog

Instructive ECGs in Clinical Context ----Archives, Popular Posts, and an Index of all ECGs are down the right-hand side.

e-cardiogram.com

Site de formation à la lecture de l'ElectroCardioGramme.